

BILATERAL DELTA PHALANX OF THE PROXIMAL PHALANGES OF THE GREAT TOES

A REPORT ON AN AFFECTED FAMILY

M. J. NEIL, C. CONACHER†

From The Wollongong Hospital, Wollongong

The condition known as delta phalanx (or longitudinally bracketed epiphysis) is a rare congenital anomaly first described in 1964. The deformity consists of a triangular bone with an epiphysis running along the shortened side of the phalanx in a proximal to distal direction, making longitudinal growth of the digit impossible. Isolated hallux varus congenitus due to a delta phalanx of the proximal phalanges of both great toes is extremely rare: there have been only three such cases reported, two of which were in one family—the only report of a familial occurrence of this deformity.

This present report details the occurrence of isolated bilateral hallux varus congenitus in four members of one family, a father and his three eldest children. All three children show bilateral delta phalanx of the proximal phalanges of both great toes. There are associated thumb nail anomalies, but no suggestion of polydactylism.

The condition known as delta phalanx or longitudinally bracketed epiphysis (Theander and Carstam 1974) was first described in 1964 by Blundell Jones, who reported five male patients with congenital angular deformity of the finger in which “the bone is triangular in shape and has a continuous epiphysis running from the proximal to the distal end along the shortened side” (Fig. 1).

The Greek letter Δ is triangular in form, but the abnormal bone that has been given this label is usually trapezoidal in shape. Jones felt that this peculiar arrangement of the epiphysis made longitudinal growth of the digit impossible and progressive angulation inevitable. He reported no family history of deformity, but noted other congenital anomalies in four cases. There were no cases involving the phalanges of the toes.

Watson and Boyes (1967) then reviewed 154 patients with congenital anomalies of hands and feet and found 22 who had one or more bones with the delta phalanx deformity. They suggested from their study that the condition was “routinely a manifestation of polydactylism”, and that the involved digital ray was “duplicated” in 26 out of their 28 cases of delta phalanx. The great toe was involved in only three cases and there were no bilateral cases reported. They concluded that delta phalanx occurs in tubular bones of the hand or foot which have a proximal epiphysis. These tubular bones become

the site of origin of an extra skeletal ray (Fig. 2). The bone takes on a peculiar trapezoidal shape since its proximal epiphysis is shared and tethered by the supernumerary ray.

Delta phalanx has also been associated with the most severe form of clinodactyly (Sharrard 1979), which has in turn also been described as an associated skeletal

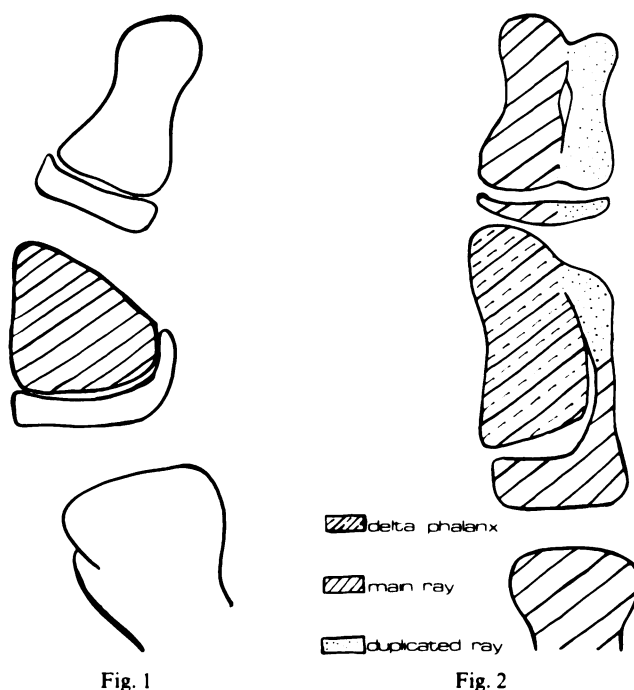


Fig. 1

Fig. 2

Figure 1—Diagrammatic representation of Jones' delta phalanx. Figure 2—Diagrammatic representation of Watson and Boyes' supernumerary ray theory of aetiology of delta phalanx.

M. J. Neil, MBBS, Orthopaedic Registrar
The Sutherland Hospital, Caringbah, Box 21, PO, Caringbah, New South Wales 2229, Australia.

† C. Conacher, MCh Orth, FRCS, deceased.

© 1984 British Editorial Society of Bone and Joint Surgery
0301-620X/84/1020 \$2.00

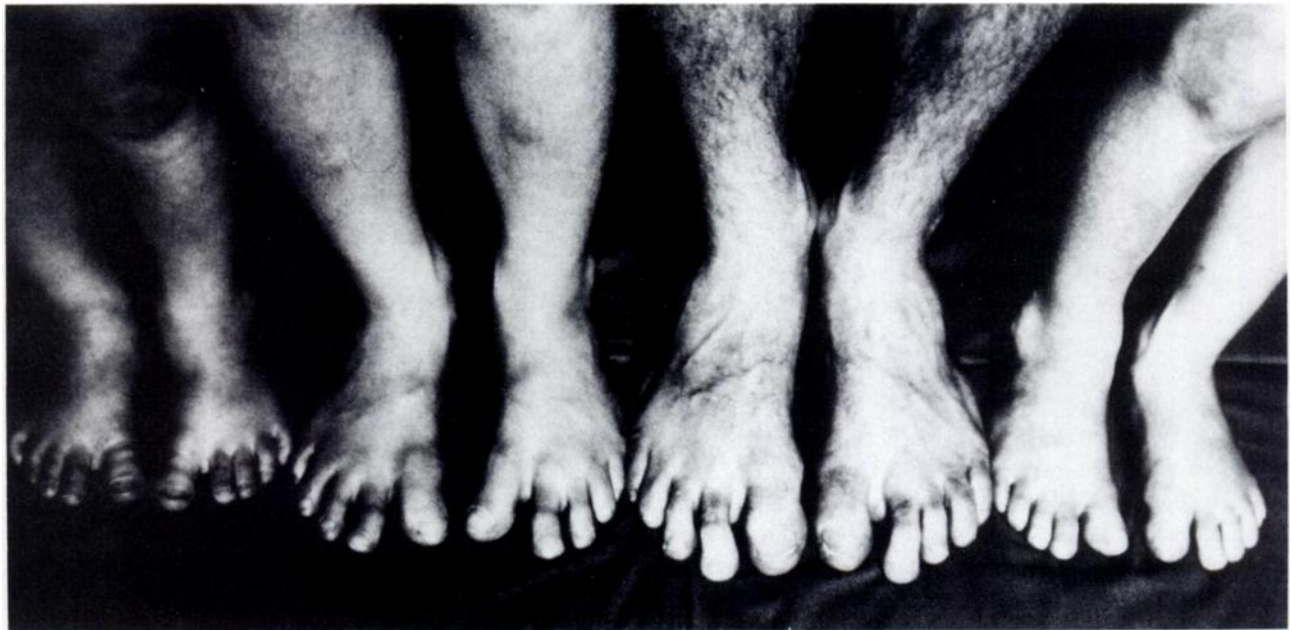

Fig. 3

Four members of one family with isolated bilateral hallux varus congenitus, the deformity being secondary to delta phalanx.

abnormality in hereditary onycho-osteodysplasia or nail-patella syndrome (Cowell 1971).

FAMILY CASE REPORT

This report details the occurrence of isolated bilateral hallux varus congenitus in four members of one family (Fig. 3), the deformity being due to delta phalanx. The affected members (Fig. 4) are the father aged 30, and his three eldest children, a girl aged seven and two boys aged four and three. The youngest and fourth child, aged six months, is normal at present. All three affected children were noted to have bilateral hallux varus at birth, but their deformity has undoubtedly progressed in severity as they grow older. Radiographically all three children

show evidence of bilateral delta phalanx of the proximal phalanges of the great toes (Figs 7, 9 and 11).

The father of these children has, like them, clinical isolated bilateral hallux varus but appears radiographically to have undergone spontaneous fusion of the left interphalangeal joint of the great toe, and partial fusion of the right (Fig. 5). The distal interphalangeal joints of his other toes have also undergone spontaneous fusion. Obviously, one would not expect to see, in a 30-year-old whose epiphyses have long since fused, how the delta phalanx developed. However, in view of this man's clinical deformity plus radiographic evidence of delta phalanx in his three affected children with almost identical clinical deformities, perhaps what we see now radiographically is the "end-stage" of delta phalanx of the proximal phalanges of his great toes.

Of note, also, with this family is the peculiar shape of the base of the nails of the thumbs and great toes in the affected members. The base of the thumb nail extends more proximally onto the radial side of the thumb (Figs 6, 8, 10, 12) and, similarly, the nail of the great toe extends further proximally on the tibial side (Fig. 3).

It appears that the clinical deformity of bilateral hallux varus and associated stiffness of the interphalangeal joints of the thumbs and great toes is more severe as the affected person gets older; that is, the deformity appears to be progressive (Fig. 13).

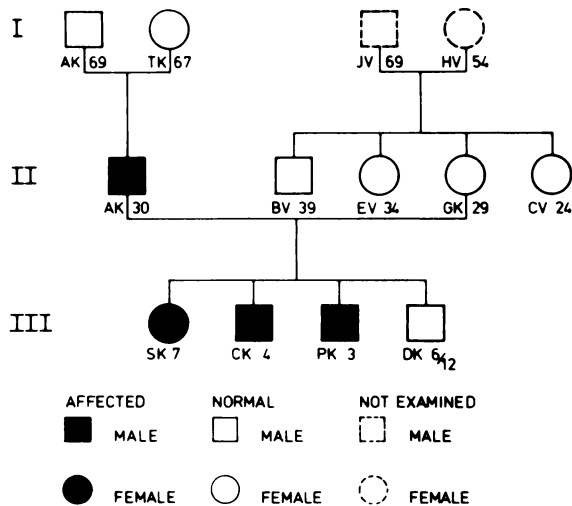


Fig. 4
Family pedigree.

DISCUSSION

Congenital deviation of the first ray of the foot into varus has been reported with polydactyly (Mestern 1933). Pollex varus and hallux varus congenitus produced by triangular deformity of the proximal phalanges has been described as part of acrocephalosyndactyly or Apert's

Radiographs of feet
and pictures of thumbs.

Father aged 30

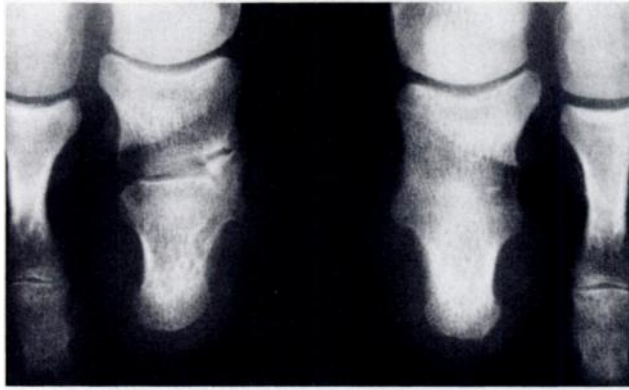

Fig. 5

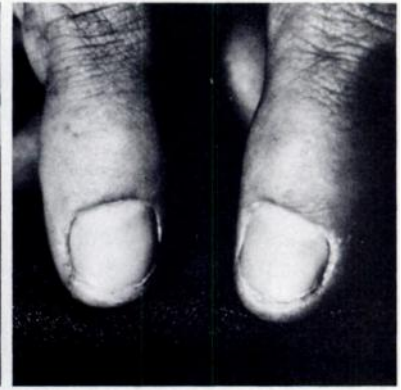

Fig. 6

Daughter aged 7

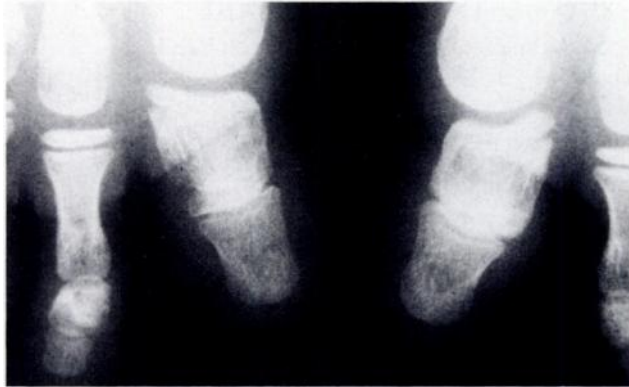

Fig. 7

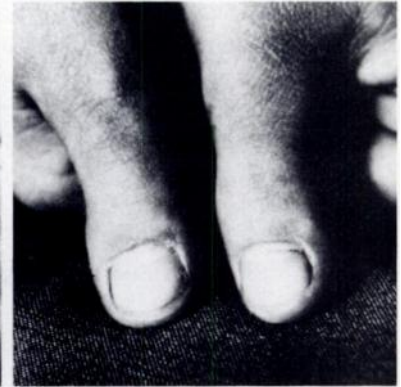

Fig. 8

Son aged 4

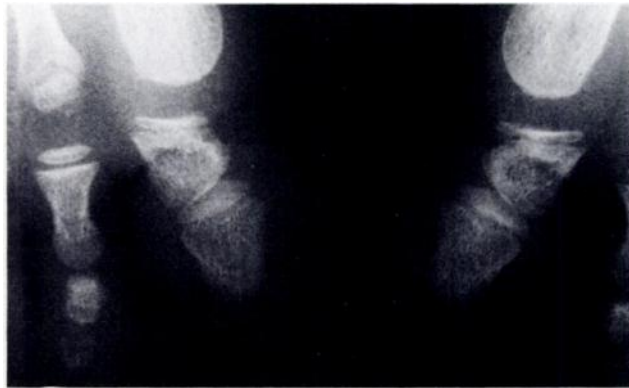


Fig. 9

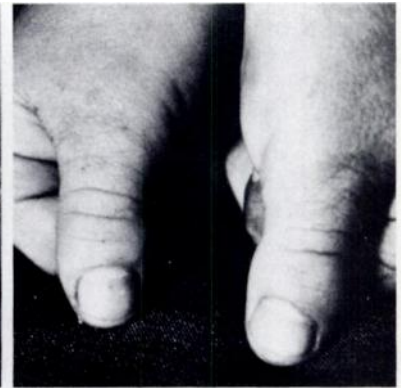

Fig. 10

Son aged 3

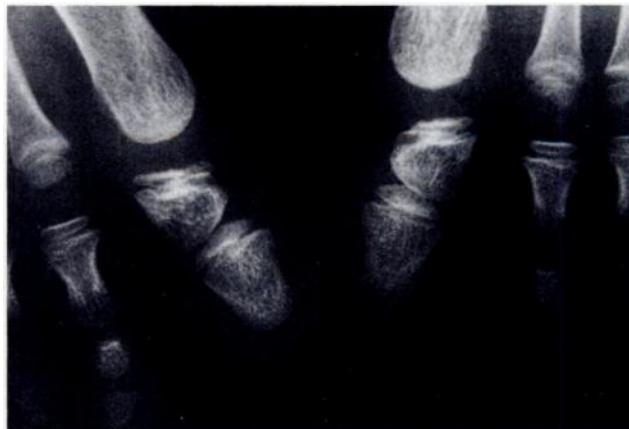

Fig. 11

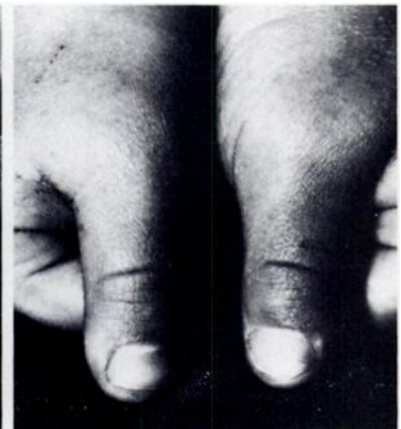

Fig. 12

syndrome. Jaeger and Refior (1971) observed one patient with Rubenstein-Taybi syndrome whose proximal phalanges of both thumbs and both great toes showed delta phalanx. However, there is no doubt that isolated hallux varus congenitus is extremely rare.

There have previously been only three reported cases of isolated bilateral hallux varus congenitus due to delta phalanx of the proximal phalanges of both great toes. Cocchi (1952) reported a five-year-old girl whose proximal and middle phalanges of both great toes were affected. Jaeger and Refior (1971), in a review of 145 patients with congenital hand and foot anomalies, were able to find only two cases with this deformity. It was present in a father and daughter, the only other report of a familial occurrence of the deformity. The present report of isolated bilateral hallux varus congenitus in four members of one family shows that the deformity progresses with age.

We were unable to confirm the duplication theory of Watson and Boyes (1967) as there was no associated polydactylism in our patients.

The authors would like to thank Mr J. Barker for preparing the charts and illustrations.

GENERATN.	INITIAL	AGE	GT. TOES	THUMBS
II	A.K.	30	XXX	XX
III	S.K.	7	XX	XX
III	C.K.	4	XX	X
III	P.K.	3	X	X-
III	D.K.	$\frac{6}{12}$	-	-

SEVERITY OF DEFORMITY

XXX FUSION
 XX SEVERE
 X MILD
 - NORMAL

Fig. 13

Family chart, illustrating the progressive worsening of deformity with age.

REFERENCES

- Cocchi V. Erbschaeden mit Knochenveraenderungen. Lehrbuch der Roentgendiagnostick. Bd I, 6. Aufl hrs 6. Von Schinz HR, Baensch WE, Friedl E, Uehlinger E. Stuttgart: Thieme, 1952.
- Cowell HR. Hereditary onycho-osteodysplasia: report of a kindred with dysplasia of the fifth finger. *Clin Orthop* 1971; **76**: 43-53.
- Jaeger M, Refior HJ. The congenital triangular deformity of the tubular bones of hand and foot. *Clin Orthop* 1971; **81**: 139-51.
- Jones GB. Delta phalanx. *J Bone Joint Surg [Br]* 1964; **46-B**: 226-8.
- Mestern J. Hallux varus congenitus und Polydaktylie. *Z Orthop* 1933; **59**: 563-82.
- Sharrard WJW *Paediatric orthopaedics and fractures*. 2nd ed. Oxford, London, Edinburgh, Melbourne: Blackwell Scientific Publications, 1979: 308-9.
- Theander G, Carstam N. Longitudinally bracketed diaphysis. *Ann Radiol* 1974; **17** (4): 355-60.
- Watson HK, Boyes JH. Congenital angular deformity of the digits: delta phalanx. *J Bone Joint Surg [Am]* 1967; **49-A**: 333-8.